

# Androgenetic alopecia in males: a histopathological and ultrastructural study

Moetaz El-Domyati, MD, Sameh Attia, MD, Fatma Saleh, MD, & Hossam Abdel-Wahab, MD

Department of Dermatology, Faculty of Medicine, Al-Minya University, Al-Minya, Egypt

## Summary

**Background** Androgenetic alopecia is a common cosmetic hair disorder, resulting from interplay of genetic, endocrine, and aging factors leading to a patterned follicular miniaturization. Microinflammation seems to be a potential active player in this process.

**Aims** To study the histopathological and ultrastructural changes occurring in male androgenetic alopecia (AGA).

**Patients/methods** Fifty-five subjects were included in this study (40 with AGA and 15 as normal age-matched controls). Skin biopsies from frontal bald area and occipital hairy area were subjected to histopathological examination, immunohistochemical staining for collagen I and ultrastructural study.

**Results** The frontal bald area of patients showed highly significant increase in telogen hairs and decrease in anagen/telogen ratio and terminal/vellus hair ratio ( $P < 0.001$ ). Perifollicular inflammation was almost a constant feature in early cases and showed a significant inverse correlation with perifollicular fibrosis ( $P = 0.048$ ), which was more marked with thickening of the follicular sheath in advanced cases.

**Conclusion** Follicular microinflammation plays an integral role in the pathogenesis of AGA in early cases. Over time, thickening of perifollicular sheath takes place due to increased deposition of collagen, resulting in marked perifollicular fibrosis, and sometimes ends by complete destruction of the affected follicles in advanced cases.

**Keywords:** microinflammation, histopathology, androgenetic alopecia, collagen, ultrastructure

## Introduction

Androgenetic alopecia (AGA) is the most common form of human hair loss, which affects at least 50% of men by the age of 50 years and up to 70% of men in later life.<sup>1</sup> In men, it is commonly referred to as male pattern alopecia or hair loss.<sup>2</sup>

Androgenetic alopecia is the result of interplay of genetic, endocrine and aging factors.<sup>3</sup> The genetically predisposed hair follicles are the target for androgen-stimulated hair follicle miniaturization, leading to gradual replacement of large, pigmented hairs (terminal hairs) by barely visible, depigmented hairs (vellus hairs) in affected areas.<sup>4</sup> The end result is a progressive decline in visible scalp hair density which occurs in a defined pattern.<sup>5</sup>

A model for the pathogenesis of AGA must account for the histological features of miniaturization of the hair follicle and an increase in the ratio of telogen to anagen hairs, the systemic and local effects of androgens in

Correspondence: Moetaz M. El-Domyati, MD, Department of Dermatology, Faculty of Medicine, Al-Minya University, 2 Obour Buildings, Salah Salem St, Apt. 53, Nasr City, Cairo 11371, Egypt.  
E-mail: moetazeldomyati@yahoo.com; m\_domyati@hotmail.com

Accepted for publication January 24, 2009

promoting the condition, and genetic predisposition.<sup>6</sup> The implication of various activators of inflammation in the etiology of AGA has progressively emerged from several independent studies.<sup>7–9</sup>

The limited success rate of treatment of AGA with hair growth promoters or modulators of androgen metabolism means that further pathogenic pathways may be taken into account.<sup>4</sup> Meanwhile, the fact that the affected hairs, although small, are not usually lost provides hope that suitable treatment can regrow them to a size large enough to reverse hair thinning. A better understanding of the miniaturization process may provide clues for identifying new approaches to treatment.<sup>10</sup> The present study aims to examine the histopathological and ultrastructural changes occurring in various grades of male AGA.

## Patients and methods

This study has been conducted on 55 male subjects, attending the dermatology outpatient clinic, Al-Minya University Hospital, Al-Minya, Egypt. Forty of them were complaining of AGA and 15 age-matched normal controls were not suffering from AGA.

The 40 patients were classified according to age into three different age groups (young, middle, and old age groups) with five age-matched controls for each group (Table 1). The patients were also classified into three clinical groups (mild, moderate, and advanced AGA) according to the severity of baldness based on Hamilton–Norwood's classification<sup>11</sup> (Table 2).

Controls were chosen from patients who were undergoing dermatosurgical procedures for another scalp condition apart from AGA. Both patients and controls underwent full history taking, general and local examination, hair pull test, trichogram and skin biopsy. Informed consent was obtained from all patients as well as controls before taking biopsy specimens. The study

**Table 1** Age groups (patients and controls) and duration of baldness of patients.

Age group	Decade	AGA			Controls age (years)
		n (%)	Age (years)	Duration (years)	
Young	2nd–3rd	15 (37.5)	21.1 ± 2.66	2 ± 1.19	20.4 ± 2.7
Middle	4th–5th	10 (25)	37.4 ± 5.32	7.6 ± 5.25	39.4 ± 6.23
Old	6th, 7th and 8th	15 (37.5)	63.7 ± 8.51	36.7 ± 13.54	63.8 ± 8.07
Total	–	40	41.15 ± 19.75	16.43 ± 18.2	41.2 ± 19.23

**Table 2** Patient groups according to the severity of baldness

Severity of AGA	Hamilton's grade	Cases	Total, n (%)
Mild	I	3	10 (25)
	II	4	
	IIa	3	
Moderate	III	1	20 (50)
	IIIa	1	
	IIIv	5	
	IV	3	
	IVa	3	
	V	5	
Advanced	Va	2	10 (25)
	VI	8	
	VII	2	
Total	–		40 (100)

was approved by the Committee for Postgraduate Studies and Research of Al-Minya University.

## Hair-pull test

About 20 hairs were held firmly between thumb and forefinger, and a firm, steady traction was placed on the hairs. More than six hairs per pull were considered abnormal.

## Trichogram

The trichogram was performed 4 days after the last hair wash. The hairs were first cut to about 2 cm above the scalp surface for better grip. Tightly closing spade-ended epilating forceps were placed as close to the skin as possible, and about four to seven hairs at a time were extracted by rapid tug in the direction of hair growth from the frontal and occipital area of the scalp. A total of 50 hairs were removed. The plucked hairs were placed as a group on a microscopic slide and mounted with Canada Balsam and examined by light microscopy.

## Histopathological study

Four-millimeter punch biopsies were taken from the frontal bald area of AGA, the occipital hairy nonbald area of AGA as well as the frontal area of normal controls. The biopsy was extended into the subcutaneous fat to include the bulbs of terminal anagen hairs. The specimens were bisected parallel to the direction of hairs, one half sectioned vertically, while the other was sectioned horizontally. The specimens were fixed immediately in 10% neutral, buffered formalin solution, embedded in paraffin blocks, sectioned by microtome into 5-μm-thick sections. The resulting sections were

mounted on glass slides and stained with hematoxylin and eosin for light microscopy.

Immunohistochemical staining for collagen type I was performed for 20 biopsy specimens (15 from the frontal bald area of AGA and five from the frontal area of controls) using rabbit anticollagen I (BIOGENESIS® cat. no. 2150-0020, Kingston, NH, USA) with a ready-to-use detection system (Ultravision detection system anti-polyvalent, HRP/DAB, Lab Vision Corporation® cat. no. TP-015-HD, Fremont, CA, USA) according to the manufacturer's instructions. Specimens were examined using a light microscope (Nikon, Optiphot 1, Japan). Photographs were taken by a Nikon digital camera.

Ultrastructural study using electron microscopy was performed for 20 biopsy specimens (15 from the frontal bald area of AGA and five from the frontal area of controls). Biopsies were fixed in a 3% buffered glutaraldehyde fixative solution for 1.5–2 h at 4 °C, washed with the cacodylate buffer solution, pH 7.3 for 15 min at 4 °C, and then placed in the buffer solution and kept at 4 °C. The tissue is post-fixed in 1% buffered osmium tetroxide, dehydrated in ascending grades of ethyl alcohol, and then embedded in Epon 812.

Sectioning was carried out using Nova ultramicrotome, stained with uranyl acetate and lead citrate, and interpretation of the sections was performed using JEOL 100 C-X transmission electron microscope, JEOL Ltd., Tokyo, Japan.

### Statistical analysis

Data were coded, entered, and analyzed using SPSS software package for statistical science (SPSS for Windows, Version 13.0.1; SPSS Inc., Chicago, IL, USA). Statistical analysis included descriptive analysis as mean value and standard deviation (SD), paired samples Student's *t*-test, independent samples *t*-test, and correlation coefficient (*r*) that were expressed in terms of *P*-value. A value of  $P \leq 0.05$  was considered statistically significant.

## Results

In the present study, the mean age of the patients was  $41.15 \pm 19.75$  years and of the controls was  $41.2 \pm 19.23$ . The duration of baldness ranged from 1 to 55 years with a mean duration of  $16.43 \pm 18.2$  years (Table 1). Half of the patients were suffering from moderate severity of AGA (Table 2). The severity of AGA showed a highly significant correlation with both the age of the patients and the duration of baldness ( $r = 0.7$ ,  $r = 0.62$ , respectively,  $P < 0.001$ ).

### Hair pull test

The tests were positive in 18 patients (45%) with mild-to-moderate AGA (with duration  $\leq 3$  years), with a mean of  $8 \pm 2$  hairs plucked at each pull from the frontal bald area. In contrast the test was negative in all the normal controls, the occipital hairy area of patients, and frontal area of AGA patients of duration longer than 5 years.

### Trichogram

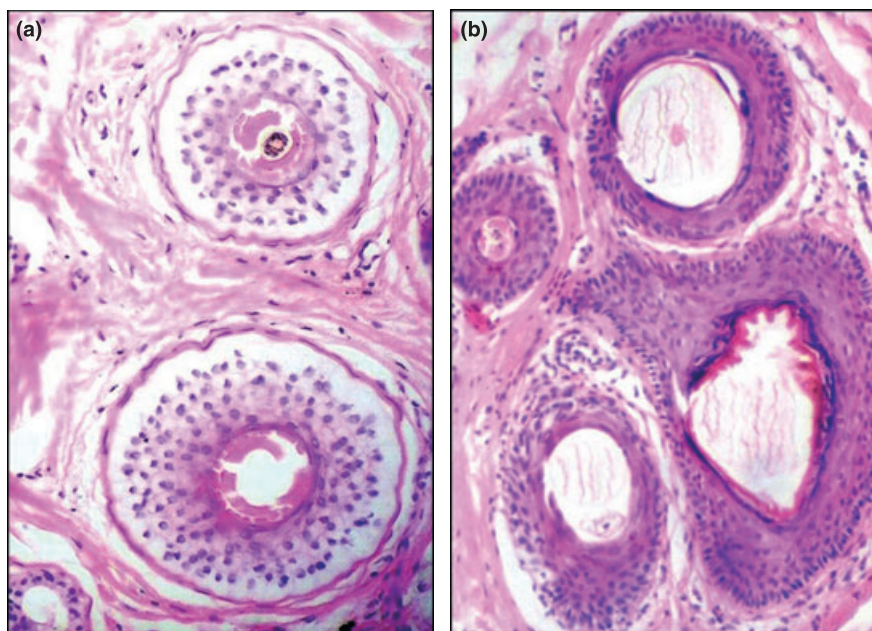
The trichogram of patients with AGA showed a highly significant decrease in anagen with a mean of 79.5%, associated with an increase in telogen (18.9%) which resulted in a lower anagen/telogen (A/T) ratio (4.2) when compared with the normal controls (85.2%, 14.8%, and 5.76, respectively) ( $P < 0.001$ ). The A/T ratio significantly correlated with the severity of baldness ( $P = 0.01$ ).

### Histopathological changes

The most striking histopathologic finding in transverse sections of AGA was the progressive miniaturization of terminal follicles. There was a reduction in follicle size and hair shaft diameter. The terminal follicles became smaller and miniaturized to vellus-like hairs. In patients with AGA, the mean terminal/vellus ratio was 2.3:1 and showed a significant difference when compared with that of the controls (7:1;  $P < 0.001$ ) (Figure 1a,b). Terminal/vellus ratio showed significant inverse correlation with both age of the patients and severity of baldness ( $r = -0.39$ ,  $P = 0.01$ , and  $r = -0.29$ ;  $P = 0.04$ , respectively).

Vertical sections showed no epidermal changes in all cases. The most conspicuous histologic feature of AGA is the presence of clusters of abnormal inflamed streamers or fibrous tracts which are strands of connective tissue, extending downwards from the hair follicle (Figure 2a). The perifollicular and perivascular inflammatory infiltrate was composed mainly of lymphocytes and histiocytes. It was more concentrated around the upper portion of the hair follicles (around the lower portion of the infundibulum and isthmus). The sebaceous glands are increased in size, number, and lobulation (Figure 2b).

In the frontal (bald) area, perifollicular inflammatory infiltrate was mild in 21 cases (52.5%), moderate in 12 cases (30%), marked infiltrate in three cases (7.5%), and only four cases (10%) showed no inflammatory infiltrate, whereas the occipital (hairy) area showed no inflammation in 33 cases (82.5%) and mild infiltrate in seven cases (17.5%).



**Figure 1** Transverse section of frontal bald area of AGA (a) showing vellus hairs and empty follicles, whereas frontal area of controls (b) showing terminal hairs (H&E,  $\times 100$ ).

In the frontal bald area of AGA, perifollicular fibrosis consisting of loose concentric layers of collagen was generally absent in 16 cases (40%) or mild in 14 cases (35%) in young age with mild AGA (Figure 2c). It was more marked, even with destruction of follicular structures, in the old age group with advanced AGA. The arrector pili muscle may be retained (Figure 2d).

Perifollicular fibrosis showed highly significant correlation with both age of the patients ( $r = 0.78$ ,  $P < 0.001$ ) and correlated significantly with the severity of baldness ( $r = 0.46$ ,  $P = 0.003$ ). It showed significant inverse correlation with perifollicular inflammation ( $r = -0.31$ ,  $P = 0.048$ ). In normal controls, neither inflammatory infiltrate, apart from sparse perivascular infiltrate in a few biopsies, nor perifollicular fibrosis was observed in all studied specimens.

#### Evaluation of type I collagen expression

Immunohistochemical staining for collagen I revealed increased collagen deposition around the hair follicles with thickening of the perifollicular sheath in the frontal bald area which was more evident in old age with advanced AGA when compared with normal controls (Figure 3a,b).

#### Ultrastructural examination

In normal controls, relatively thin follicular sheath was observed. Fibroblasts are within normal number with

normal activity (Figure 4a). The mast cells showed numerous intact granules with no evidence of degranulation (Figure 4b).

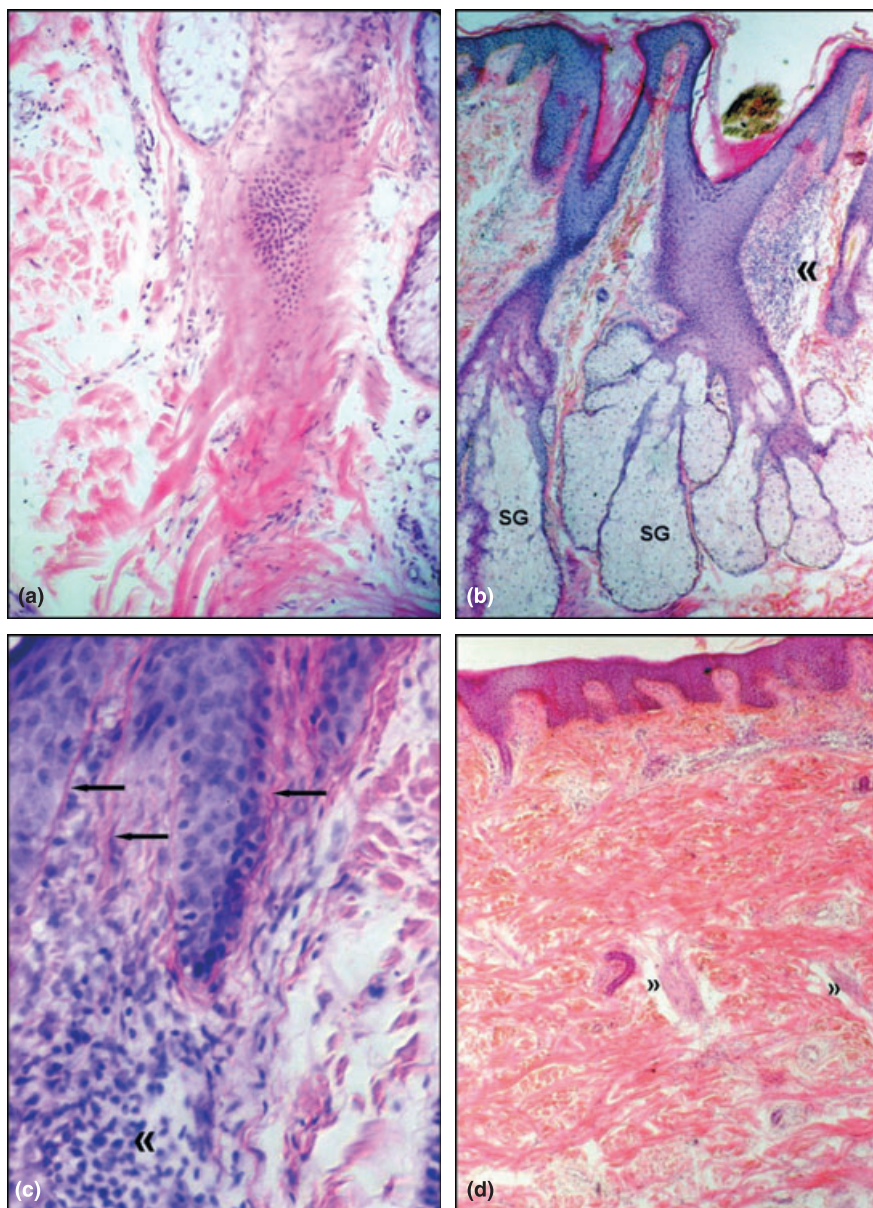
In early (mild and moderate) AGA, mononuclear cellular inflammatory infiltrate, composed predominantly of lymphocytes and mononuclear cells, was distributed within the adventitial sheath. The mast cells were increased in number and showed degranulation which became marked in advanced AGA, leaving mast cells with few or even no intact granules (Figure 4c). Fibroblasts were increased in number and activity. They showed prominent mitochondria and Golgi zones. The rough endoplasmic reticulum was dilated. They displayed evidence of peripheral secretion of procollagen filaments. The follicular sheath was thickened compared with normal control (Figure 4d).

In late (advanced) AGA, the follicular sheath is markedly thickened and widened by densely packed collagen bundles secreted by fibroblasts denoting marked fibrosis. Many elongated and tortuous elastic fibers were also observed denoting increased elastosis (Figure 4e,f).

#### Discussion

Androgenetic alopecia is a common androgen-induced progressive disorder, the pathogenic pathways of which are regulated by local genetic codes and hormonal control.<sup>12</sup> Microinflammation seems to be a potential active player in this process.<sup>9</sup>





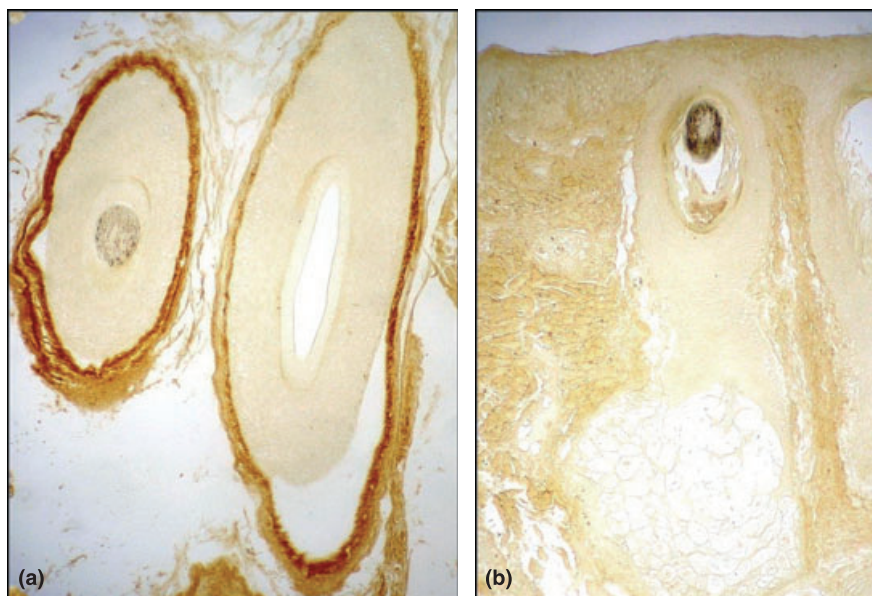
**Figure 2** Vertical section of frontal bald area of AGA showing: (a) replacement of the lower portion of the hair follicle by fibrous tract. (b) Marked perifollicular inflammatory infiltrate around the upper portion of hair follicle («). Sebaceous glands are increased in size and lobulation (SG). (c) Vertical strands of collagen bundles around hair follicle (←). (d) Late AGA shows marked fibrosis, absence of follicular structure, and retained arrector pili muscles (») (H&E, a,c:  $\times 200$ , b,d:  $\times 32$ ).

In 1951, Hamilton<sup>13</sup> was the first to grade the severity of AGA from class I to VII and this was later modified by Norwood<sup>1</sup> by addition of variances of hair loss within these grades. Currently, this modified Norwood—Hamilton classification is the most accepted grading system for male.<sup>14</sup>

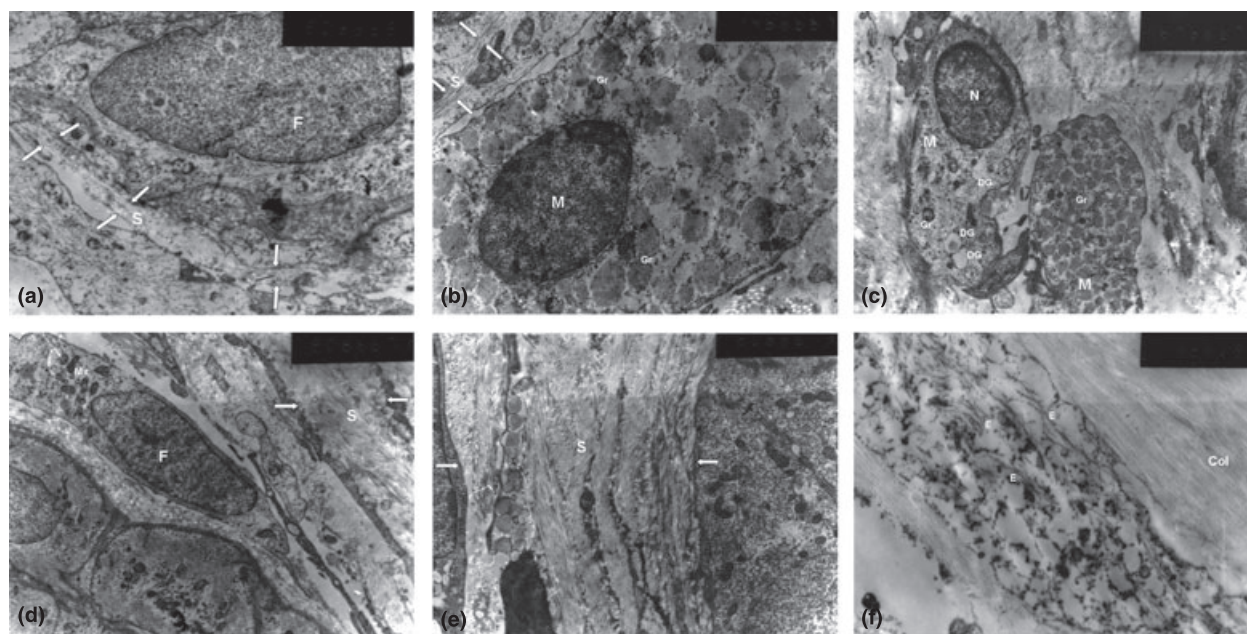
In the present study, the pattern and degree of AGA showed a highly significant correlation with both the age of the patients and the duration of

baldness ( $P < 0.001$ ). These results are in agreement with Sehgal et al.<sup>14</sup> who reported a gradual shift in the type of AGA to a more severe type with increased age.

Hairs can be extracted from the scalp for evaluation of the root structure. Pull test may be negative or reveal increased telogen shedding.<sup>15</sup> In the present study, pull test in the bald area was positive in early AGA and negative in late and advanced cases as well as the



**Figure 3** (a) Frontal bald area of AGA showing thickened layer of collagen I around hair follicles. (b) Frontal area of controls showing thin layer of collagen I (Collagen I,  $\times 100$ ).



**Figure 4** (a) Control (nonbald): thin follicular sheath (S) of the HF and fibroblast (F) (E.M.,  $\times 8000$ ); (b) Control (non-bald): thin follicular sheath (S), mast cell (M) with intact granules (Gr) (E.M.,  $\times 14\ 000$ ); (c) Early AGA: mast cells (M) shows degranulation (DG) with many intact granules (Gr) (E.M.,  $\times 6700$ ); (d) Early AGA: thick follicular sheath (S) and active fibroblast with prominent mitochondria (Mit) (E.M.,  $\times 8000$ ); (e) Advanced AGA: marked thickening of follicular sheath (S) (white arrow) (E.M.,  $\times 8000$ ); (f) Advanced AGA: dense collagen bundles (Col) denoting marked fibrosis. Numerous degenerated elastic fibers (E) denoting elastosis (E.M.,  $\times 14\ 000$ ).

occipital hairy area of AGA and normal controls. On the other hand, El-Domyati et al.<sup>16</sup> reported 100% positive test in females with AGA.

The trichogram of patients with AGA showed a highly significant increase in telogen hairs with a concomitant decrease in those in anagen, referred to as a decreased



A/T ratio when compared with normal controls ( $P < 0.001$ ). These results agree with Bergfeld<sup>17</sup> and reflect a shortening of the anagen phase with a resultant relative increase in telogen follicles along with miniaturization of the hair follicles.

The histopathologic hallmark of AGA is the progressive miniaturization of terminal follicles.<sup>18</sup> Terminal hairs are decreased with an increase in vellus hairs as well as follicular stela (fibrous tracts or streamers).<sup>8</sup> Moreover, the presence of many empty follicles in AGA could be explained by the diminution of follicles<sup>19</sup> and the presence of the lag phase between shedding of resting hairs till new hairs start to grow. This produces empty follicles for a period of time.<sup>10</sup>

The presence of miniaturized hairs in AGA has a prognostic value as medical treatments, including minoxidil and finasteride, but will be effective only if there is sufficient hair to salvage, with at least miniaturized hairs to convert into terminal hairs.<sup>11</sup> The greater the number of miniaturized hairs, the better the response to treatment.<sup>20</sup>

Traditional vertical sections could demonstrate changes at the dermo-epidermal junction, within the papillary dermis, and within the subcutaneous fat but generally demonstrate only four to six follicles.<sup>8</sup> Transverse sections, introduced by Headington,<sup>21</sup> may contain 20–30 follicles in a single section. Hence, they allow accurate vellus hair counts which could be missed in vertical sections.<sup>22</sup>

In the present study, we combined findings from both sections: vertical and transverse. This combination allowed us to have better insights into histopathological changes occurring in AGA. The frontal bald area showed a highly significant decrease in terminal hairs ( $P < 0.001$ ) with an average terminal-to-vellus ratio of 2.3:1. These results agree but are slightly higher than those reported by Whiting<sup>8</sup> and El-Domyati et al.<sup>16</sup> with a terminal/vellus ratio of 2:1 and 1.8:1, respectively. A terminal-to-vellus ratio of 2:1 or less is likely to indicate increased follicular miniaturization.<sup>8</sup>

The inflammatory infiltrate was composed mainly of lymphocytes and histiocytes. It was more concentrated around the upper portion of the follicles (around the lower portion of the infundibulum and isthmus). These findings correlate with previous reports.<sup>9,16,18</sup>

Jaworsky et al.<sup>7</sup> showed that, in patients with AGA, the bulge area of the outer root sheath in the superficial portion of the hair follicle appears to be a primary target for assault by an inflammatory infiltrate. Multipotent stem cells residing in the bulge contribute to the lineages of epidermis, the sebaceous gland, and the hair follicle.<sup>23</sup>

The localization of stem cells to the bulge area of the hair follicle may explain the irreversible nature of AGA.<sup>24</sup> Chronic inflammation of streamers with fibrosis may end by partial resorption or disappearance of affected hair follicle.<sup>25</sup> Ultimately, there will be reduced follicular density.<sup>19</sup>

In the frontal (bald) area of AGA, perifollicular inflammatory infiltrate was observed in the majority of cases (90%). Meanwhile, no fibrosis was observed in 40% and only 10% showed marked fibrosis and complete destruction of hair follicles in the old age group with advanced AGA. These results are close to those observed by El-Domyati et al.<sup>16</sup> who reported inflammatory reaction in female subjects with AGA with destruction of follicular structure and replacement by fibrous tracts in severe cases. Meanwhile, Abell<sup>26</sup> reported an inflammatory reaction in 75% of balding patients, focal fibrosis in 25%, and destruction of follicular structures in 5%.

This corroborates the ultrastructural findings of mononuclear cellular inflammatory infiltrate, composed predominantly of lymphocytes and mononuclear cells, distributed within the adventitial sheath. In addition, there were increased numbers of both mast cells and activated fibroblasts which showed prominent nucleus with prominent Golgi zones and dilated rough endoplasmic reticulum. They displayed evidence of peripheral secretion of procollagen filaments. Jaworsky et al.<sup>7</sup> and El-Domyati et al.<sup>16</sup> reported similar findings.

Kligman<sup>25</sup> demonstrated that perifollicular fibrosis was due to deposition of concentric layers of perifollicular collagen. The perifollicular fibrosis was evidenced by degranulation of follicular adventitial mast cells as well as enhanced collagen production by neighboring fibroblasts which resulted in 2- to 2.5-fold enlargement of the follicular dermal sheath.<sup>27</sup>

Mast cell granules have been demonstrated to contain cytokines, such as tumor necrosis factor- $\alpha$ , which are capable of inducing proinflammatory cellular activation at the level of microvascular endothelium.<sup>28</sup> They are also implicated in the induction of cutaneous fibroplasia and collagen synthesis by sheath fibroblasts. With chronicity, such factors could contribute to permanent hair loss.<sup>29</sup>

However, whether these changes are the primary cause of the alopecia or a secondary event remains to be elucidated. These findings may also raise the question of the value of intralesional injection of steroids in conjunction with minoxidil in such cases, especially in early AGA.

Furthermore, immunohistochemical staining revealed increased collagen (type I) deposition around the hair

follicle in the frontal bald area which was more evident in advanced cases of AGA when compared with normal controls. This is supported by the study of Sperling and Winton<sup>22</sup> who observed that thickened rings of dermal collagen could be seen encircling individual follicles or small groups of follicles. In addition, thickening of the dermal sheath in progression zones of AGA showed increased expression of collagen.<sup>9</sup>

In the present study, early ultrastructural examination of AGA showed degranulation of mast cells which became marked later on, leaving mast cells with few or even no intact granules. The follicular sheath was thickened when compared with normal controls. In advanced AGA, the follicular sheath is markedly thickened and widened by densely packed collagen bundles secreted by fibroblasts denoting marked fibrosis. Meanwhile, many elongated and tortuous elastic fibers were observed denoting increased elastosis. This is in agreement with Weedon<sup>30</sup> who reported solar elastosis and some thinning of the epidermis that may also be present in cases of long-standing AGA. It is worth mentioning that gradual accumulation of elastin was reported in photoaged sun-exposed skin,<sup>31</sup> which could explain elastosis occurring in the sun-exposed bald area of AGA patients.

In conclusion, the present work has demonstrated a profound view of various histopathological and ultrastructural changes occurring in AGA. The genetically predisposed hair follicles are the target for androgen-stimulated hair follicle miniaturization. Follicular microinflammation around the upper portion of the hair follicle seems to play an integral role in the pathogenesis of AGA. Over time, there is increased deposition of collagen in the perifollicular sheath, which appears to be markedly thickened in ultrastructural examination. Ultimately, this process results in marked fibrosis and sometimes ends by even complete destruction of the hair follicle in advanced cases.

## Acknowledgments

The authors thank Dr. Helmy Abou-Elazm from the E.M. Unit of Al-Minya University Central Laboratory, for his excellent guidance and help in electron microscopy.

## References

- Norwood OT. Male pattern baldness: classification and incidence. *South Med J* 1975; **68**: 1359–65.
- Whiting DA. Male pattern hair loss: current understanding. *Int J Dermatol* 1998; **37**: 561–6.
- Mezick JA, Gendimenico GJ, Liebel FT, Stenn KS. Androgen induced delay of hair growth in the golden Syrian hamster. *Br J Dermatol* 1999; **140**: 1100–4.
- Trüeb RM. Molecular mechanisms of androgenetic alopecia. *Exp Gerontol* 2002; **37**: 981–90.
- Trüeb RM. Aging of hair. *J Cosmet Dermatol* 2005; **4**: 60–72.
- Simpson NB, Barth JH. Hair patterns: hirsutes and androgenetic alopecia. In: RPR Dawber, ed. *Diseases of the Hair and Scalp*, 3rd edn. Oxford: Blackwell Science; 1997: 177.
- Jaworsky C, Kligman AM, Murphy GF. Characterization of inflammatory infiltrates in male pattern alopecia: implications for pathogenesis. *Br J Dermatol* 1992; **127**: 239–46.
- Whiting DA. Diagnostic and predictive value of horizontal sections of scalp biopsy specimens in male pattern androgenetic alopecia. *J Am Acad Dermatol* 1993; **28**: 755–63.
- Mahé YF, Michelet JF, Billoni N, Jarrousse F, Buan B, Commo S, Saint-Léger D, Bernard BA. Androgenetic alopecia and microinflammation. *Int J Dermatol* 2000; **39**: 576–84.
- Whiting DA. Possible mechanisms of miniaturization during androgenetic alopecia or pattern hair loss. *J Am Acad Dermatol* 2001; **45**(Suppl. 2): 81–6.
- Shapiro J. Androgenetic alopecia: pathogenesis, clinical features and practical medical treatment. In: J Shapiro, ed. *Hair Loss: Principles of Diagnosis and Management of Alopecia*. London: Martin Dunitz Ltd; 2002: 83.
- Matilainen VA, Keinänen-Kiukaanniemi SM. Hormone-induced aberrations in electromagnetic adhesion signaling as a developmental factor of androgenetic alopecia. *Med Hypoth* 2002; **58**: 261–3.
- Hamilton JB. Patterned hair loss in man: types and incidence. *Ann NY Acad Sci* 1951; **53**: 708–28.
- Sehgal VN, Kak R, Aggarwal A, Srivastava G, Rajput P. Male pattern alopecia in an Indian context: a perspective study. *J Eur Acad Dermatol Venereol* 2007; **21**: 473–9.
- Tosti A, Piraccini BM. Androgenetic alopecia. *Int J Dermatol* 1999; **38**: 1–7.
- El-Domyati M, Abdel-raouf H, El-Ammawi T, Said E. Androgenetic alopecia and telogen effluvium: a comparative trichogram, histopathological and ultrastructural study. *Egypt J Derm Venereol* 2002; **22**: 45–52.
- Bergfeld WF. Alopecia: histologic changes. *Adv Dermatol* 1989; **4**: 301–22.
- Sellheyer K, Bergfeld WF. Histopathologic evaluation of alopecias. *Am J Dermatopathol* 2006; **28**: 236–59.
- Abell E. Inflammatory diseases of the epidermal appendages and of cartilage. In: D Elder, R Elenitsas, C Jaworsky, B Jhonson, Jr, eds. *Lever's Histopathology of the Skin*, 8th edn, Ch. 18. Philadelphia, PA: Lippincott-Raven; 1997: 18.
- Shapiro J, Price VH. Hair growth: therapeutic agents. *Dermatol Ther* 1998; **16**: 341–56.
- Headington JT. Transverse microscopic anatomy of the human scalp. *Arch Dermatol* 1984; **120**: 449–56.



- 22 Sperling LC, Winton GB. The transverse anatomy of androgenetic alopecia. *J Am Acad Dermatol* 1990; **16**: 1127–33.
- 23 Barthel R, Aberdam D. Epidermal stem cells. *J Eur Acad Dermatol Venereol* 2005; **19**: 405–13.
- 24 Cotsarelis G. Hair follicle stem cells: their location and roles. In: FM Camacho, VA Randall, Price VH, eds. *Hair and its Disorders: Biology, Pathology and Management*. London: Martin Dunitz Ltd; 2000: 40.
- 25 Kligman AM. The comparative histopathology of male pattern baldness and senescent baldness. *Clin Dermatol* 1988; **6**: 108–18.
- 26 Abell E. Histologic response to topically applied minoxidil in male pattern alopecia. *Clin Dermatol* 1988; **6**: 191–4.
- 27 Mahé YF. Inflammatory perifollicular fibrosis and alopecia. *Int J Dermatol* 1998; **37**: 416–7.
- 28 Klein LM, Lavker RM, Matis WL, Murphy GF. Degranulation of human mast cells induces an endothelial antigen central to leukocytes adhesion. *Proc Natl Acad Sci USA* 1989; **86**: 8972–6.
- 29 Lee Choi K, Claman HN. Mast cell, fibroblasts and fibrosis: new clues to the riddle of mast cells. *Immunol Res* 1987; **6**: 145–52.
- 30 Weedon D. Diseases of cutaneous appendages. In: D Weedon, ed. *Skin Pathology*, 2nd edn, Ch. 15. London: Churchill Livingstone; 2002: 455.
- 31 El-Domyati M, Attia S, Saleh F, Brown D, Birk DE, Gasparro F, Ahmad H, Uitto J. Intrinsic aging vs. photoaging: a comparative histopathological, immunohistochemical, and ultrastructural study of skin. *Exp Dermatol* 2002; **11**: 398–405.